

# Screening Form for Oral Cancer Screening (All Minato City residents who are 40 years old and above this fiscal year)

(Residents born before 31 March 1979)

This Examination Sheet is valid for the following periods: June 1, 2018 to January 31, 2019

<b>Examination date</b>	Year: ____/Month: ____/Day: ____	<b>Sex</b>	Please adhere your Examination Ticket's bar code sticker here
Name in kana syllabary			
<b>Name</b>		Male Female	
<b>Date of birth</b>	Year: ____/Month: ____/Day: ____	<b>Age:</b>	
			Address:
			Tel:

Please fill in the required items in the above box and then answer the following questions before the start of your dental examination. Please circle the applicable answers.

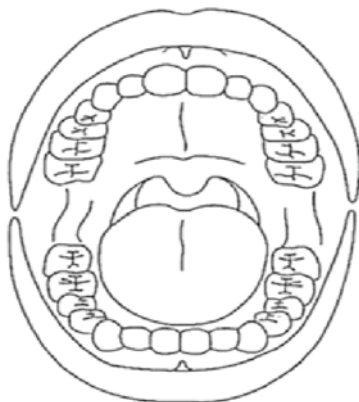
### Questions about your oral health/habits (to be filled in by the patient)

1 Do you have any oral symptoms that you are concerned about?	No / Yes (Location :    symptoms :    date symptoms began :    )
2 Are you currently taking any medication?	No / Yes (Name of medication :    )
3 Are you currently sick or unwell?	No / Yes (Name of illness:    )
4 Have you ever experienced any major illness?	No / Yes (Name of illness:    )
5 Do you have any relatives who were cancer patients?	No / Yes (Relationship :    name of illness :    )
6 Do you have any allergies?	No / Yes (What type of allergies? :    )
7 Are you/Were you a smoker?	No / Yes ( ____cigarettes/day) (smoking for ____years/ quit ____years ago)
8 Do you have a drinking habit?	No / Yes (No.    of ml per day, no.    of days per week)
9 Please write down any additional information or questions that you may have before the screening	

### 検診医記入欄

Findings from examination outside the oral cavity: No abnormalities / Abnormalities found	Area: <input type="checkbox"/> Parotid gland <input type="checkbox"/> submaxillary gland <input type="checkbox"/> submandibular lymph node <input type="checkbox"/> cervical lymph node <input type="checkbox"/> other Findings: <input type="checkbox"/> Swelling <input type="checkbox"/> tumor <input type="checkbox"/> tenderness <input type="checkbox"/> other
Findings from examination inside the oral cavity: No abnormalities / Abnormalities found	Area: <input type="checkbox"/> Upper lip <input type="checkbox"/> lower lip <input type="checkbox"/> mucous membrane of the cheeks <input type="checkbox"/> maxillary gingiva <input type="checkbox"/> mandibular gingiva <input type="checkbox"/> tongue <input type="checkbox"/> floor of the oral cavity <input type="checkbox"/> palate <input type="checkbox"/> other Findings: <input type="checkbox"/> White spots <input type="checkbox"/> redness <input type="checkbox"/> ulcers <input type="checkbox"/> inflammation <input type="checkbox"/> swelling <input type="checkbox"/> tumor <input type="checkbox"/> tenderness <input type="checkbox"/> other

Findings / Process (First screening)



Findings / Process (Second screening: date of \_\_\_\_ (mm) \_\_\_\_ (dd))

Suspicion of malignancy : No / Yes

Screening results:

No abnormalities: No oral cancer found at present.

Follow-up examination required: Minor changes were observed, requiring follow-up examination

Detailed examination required: Detailed examination at a specialist hospital is required

Screening results: No abnormalities   Follow-up examination required   Detailed examination required

Medical institution recommended:

Name of medical institution conducting the first screening

Address

Tel

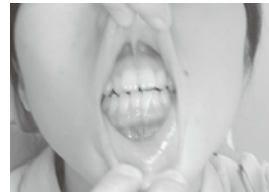Name of physician

## [What is oral cancer?]

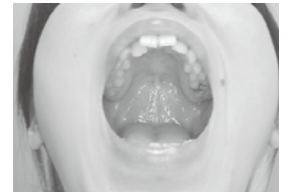With the advancement of the aging society, we are continuing to experience an increase in the incidence of oral cancer, which can arise in all the areas of the mouth. Currently, only one in five patients are receiving treatment after early detection, while patients whose cancer were detected late and for whom the disease has progressed for five years have a survival rate of about 50%. Even if cured of oral cancer, many patients face difficulty in rehabilitation to society for reasons such as a decline in eating function or changes to the shape of the face. However, in recent years, oral cancer treatment delivers a very high survival rate of 90% for cancer in the early stages. Hence, it is regarded as one of the illnesses for which early detection and early treatment are extremely important. Furthermore, as there are many parts of the oral cavity that are visible and accessible to touch, it is one of the cancers that is relatively easier to detect through a medical examination.

### First, find out more on your own!

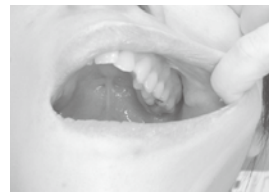- Prepare a mirror in a well-lit location.
- Remove all your dentures, etc.  
~Rinse well before you begin! ~
- Compare the right and left sides. Do you see anything unusual?
- Are there any lumps, swelling, or boils?
- Is there any redness, or white patterns that cannot be removed?
- Do you have any mouth ulcers that have not recovered after two weeks or more?
- Do you have any scratches caused by dentures or fillings?



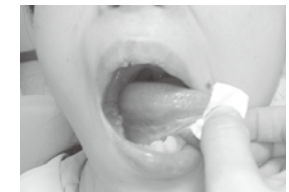Pull lips to the various directions and try to look.



Open a mouth and try to look at the depths of the throat and the back of the tooth.

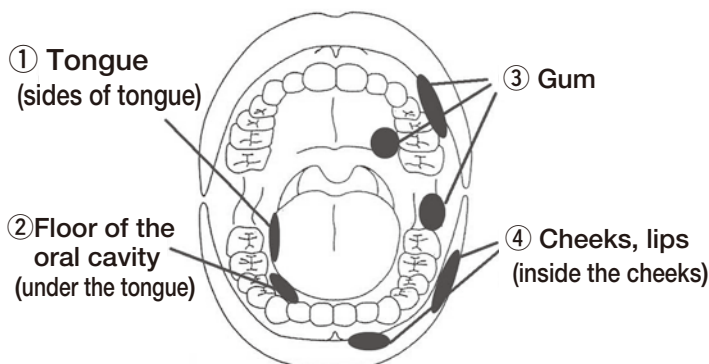


Open cheeks and try to look at the back of the tooth cervix alignment of teeth.



Pick up a tongue with a tissue and try to look at the back of the tongue.

### Which are the areas that oral cancer frequently emerge in?



### Which groups of people are susceptible to oral cancer?

- Smokers (incidence of oral cancer is three times that of non-smokers)
- Those with poor oral hygiene
- Those with a drinking habit (particularly for strong alcoholic drinks)
- Irritation from poorly fitted dentures or fillings
- Frequent consumption of hot or strongly stimulating food or beverages
- Those with a history of cancer
- Highest incidence around 60 years of age, and twice the number of male patients than women patients

## [Merits and demerits of cancer screening]

Detailed cancer screening is deemed necessary when a patient is assessed to “appear to have abnormalities (illness), including suspicion of cancer, etc.” It is necessary to conduct a detailed examination on the cause, and find out if any abnormalities are actually present. However, there are many cases where patients are found to be free of cancer upon undergoing a detailed examination. This is known as “false positive” in screening. This “false positive” is unavoidable to a certain degree, and is only identified upon a detailed examination. Hence, it is vital to undergo a detailed examination.

In consideration of this, cancer screening may also have its demerits. These include the possibility of undergoing examinations that are ultimately unnecessary, and the occurrence of procedural accidents (for example, infections, bleeding, etc.) or radiation exposure as a result of the screening procedures despite the fact that it is not 100% certain that cancer is detected, or there is a very low possibility of cancer.

Nevertheless, an invaluable merit of cancer screening lies in the fact that early detection and treatment of cancer can save lives. In particular, early detection of oral cancer can help to protect the functions of chewing, swallowing, and speaking, thereby having a significant impact on future quality of life (QOL).

In order to make good use of this merit, it is necessary to also learn about the demerits. It is important to have accurate knowledge about cancer screening, and for those who do not have cancer to continue undergoing screening at the necessary intervals.